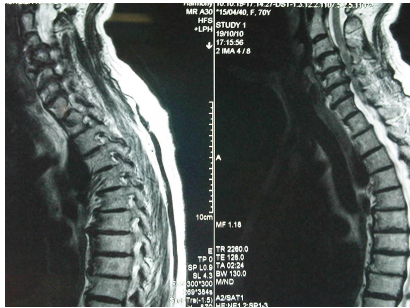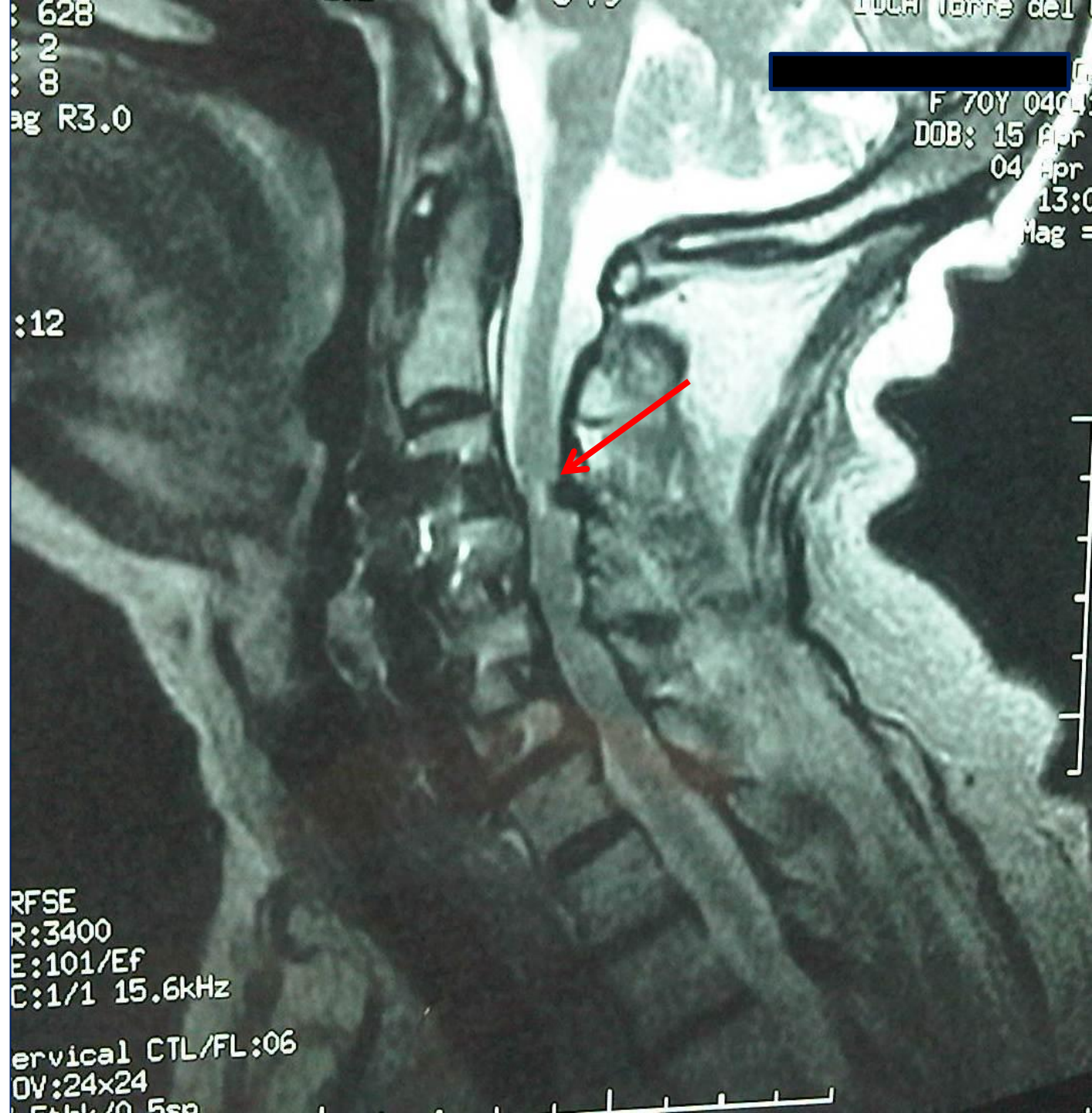

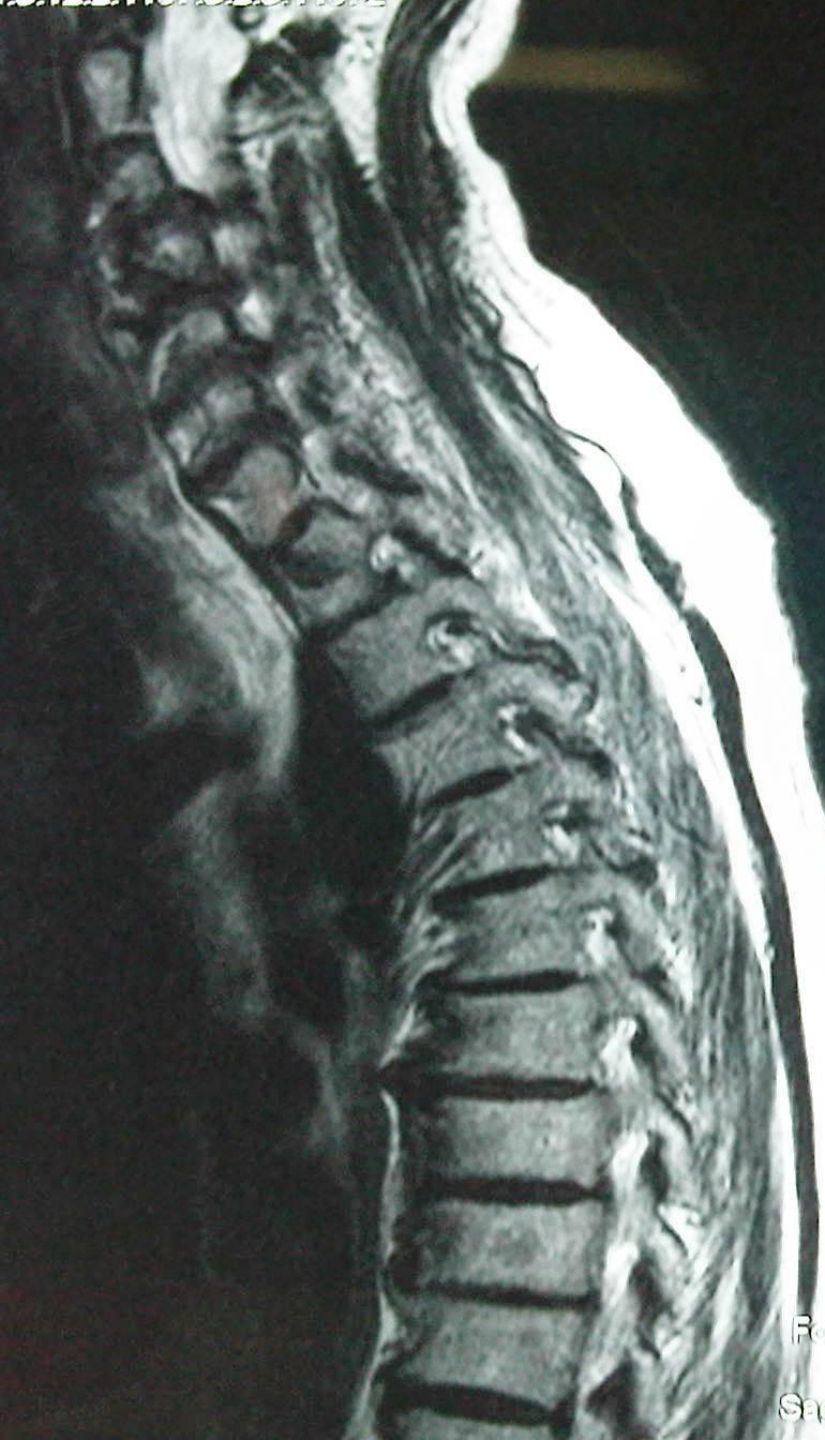
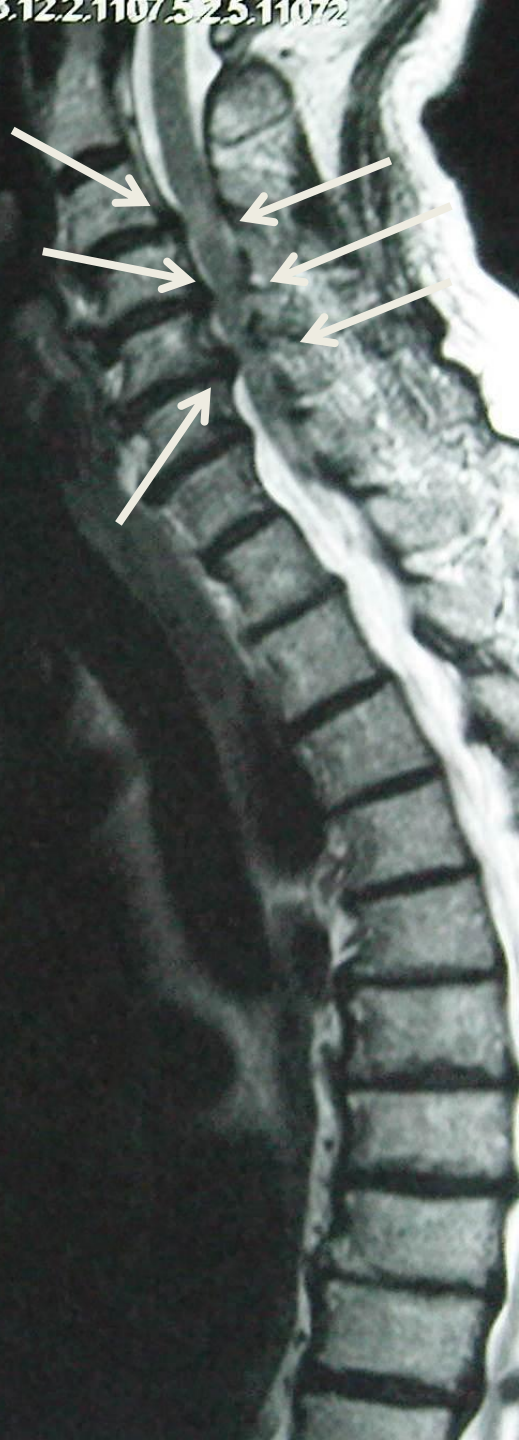# DISCECTOMIE CERVICALI MULTIPLE PER MIELOPATIA



CAS O 1 – De  
Gaetano

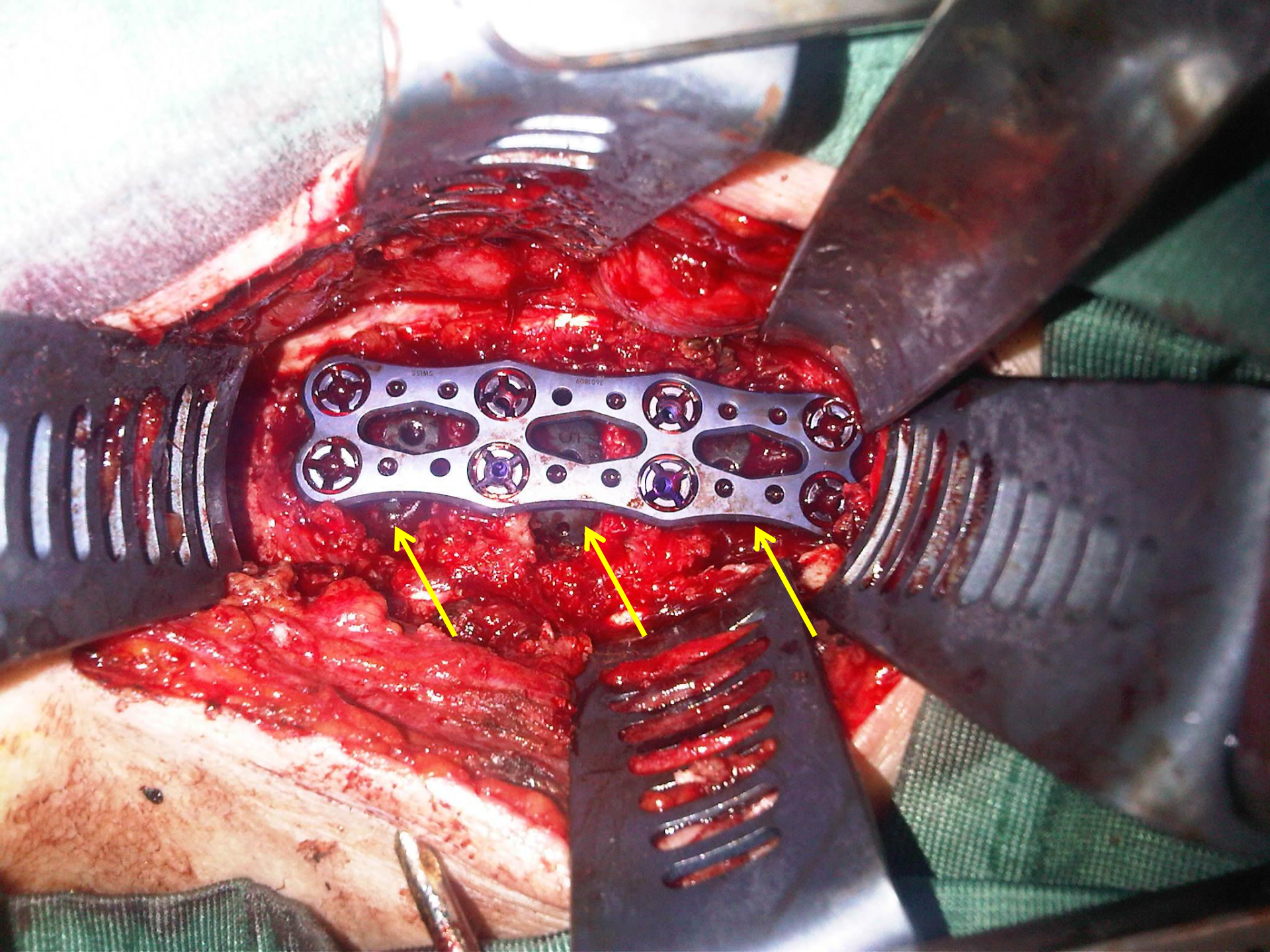


10.10.19-17:14:27-DSI-1.3.12.2.1107.525.11072  
MR A30 \*15/04/40, F, 70Y  
HFS  
+LPH  
STUDY 1  
19/10/10  
17:15:56  
↓  
2 IMA 4 / 8

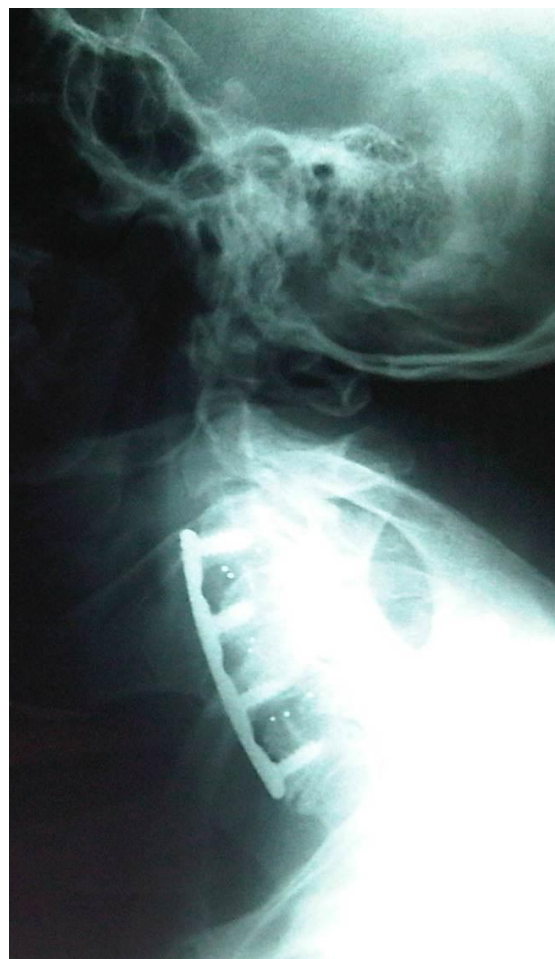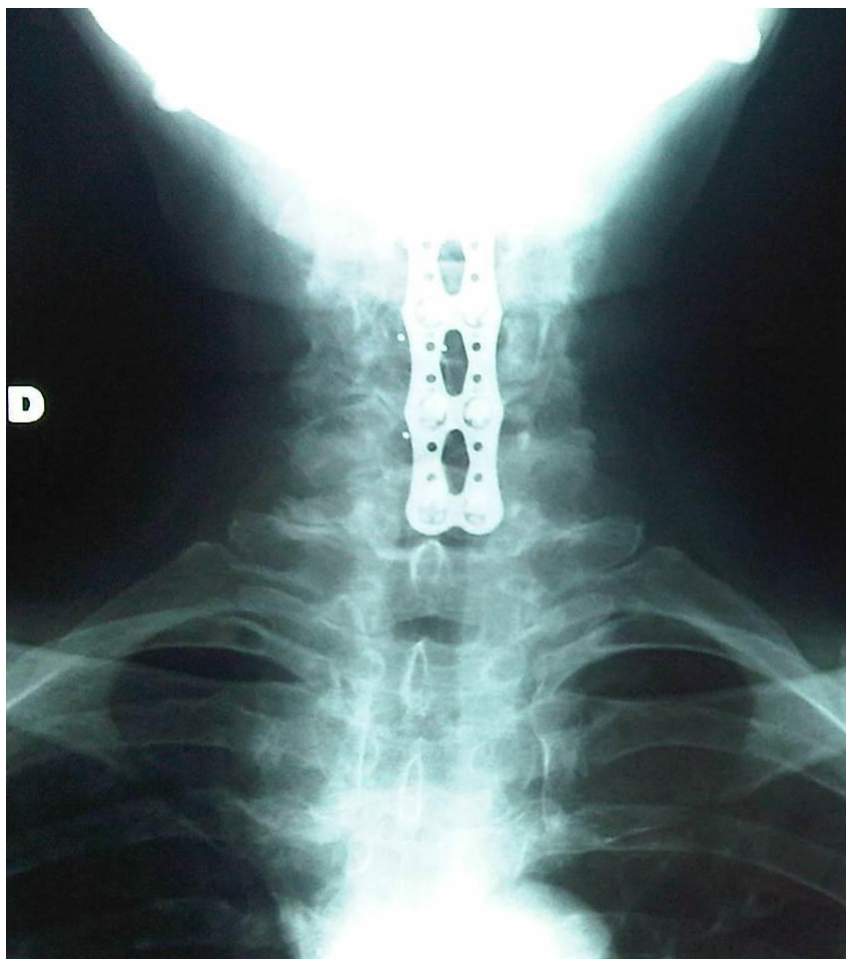


A  
10cm

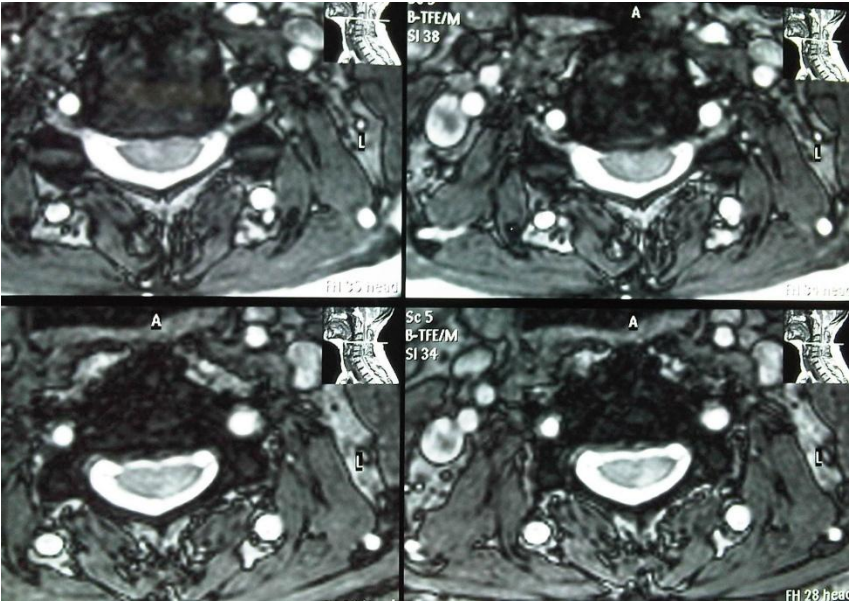
MF 1.18  
E TR 2260.0  
TP 0 TE 128.0  
SP L0.9 TA 02:24  
SL 4.3 BW 130.0  
FoV 300\*300 M/ND  
269\*384s  
Sag Tra(-1.5) A2/SAT1  
w 870 HE:NE1 2:SP1-3

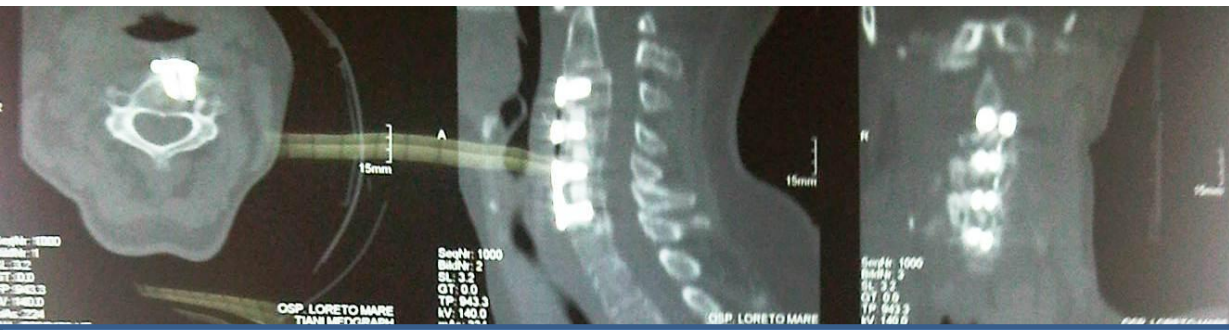

## Rx postoperatoria



# CASO 2 – Moxey Jane





TC postoperatoria

